



A CASE REPORT- SCORPION BITE WITH AUTONOMIC DYSFUNCTION AND MYOCARDIAL ISCHEMIA

Dr Nitin Jadhav

Associate Professor, Department Of Medicine, KIMS, Karad

Dr Swapnil Shinde

Junior Resident, Department Of Medicine, KIMS, Karad

Dr Akshay Kale

Junior Resident, Department Of Medicine, KIMS, Karad

ABSTRACT

Local treatment of scorpion bite includes measures to reduce pain, immobilize the affected part, apply a topical anesthetic agent to decrease paresthesia, prophylaxis administration of tetanus, administration of systemic antibiotics, combination of beta-blockers with sympathetic alpha-blockers is most effective in reversing this venom-induced effect. Such as prazosin, nifedipine, nitroprusside, hydralazine, or angiotensin-converting enzyme inhibitors are used commonly. Antivenom is the treatment of choice after stabilization. Administration of atropine to counter venom-induced parasympathomimetic effects.

KEY WORDS : myocardial ischemia, Scorpion bite, autonomic dysfunction, Cardiovascular manifestations

INTRODUCTION-

There are about 1500 species of scorpions worldwide out of these 50 are dangerous to human. Among 86 species in India, *Mesobuthus tamulus* (Indian red scorpion) and *Heterometrus swammerdami* are of medical importance.[1] Scorpion bites are common in rural India [2]. Almost all venomous scorpions, belong to the large family called Buthidae [3]. . Scorpion sting causes a variety of symptoms from local skin reaction to cardiovascular collapse, neurological and respiratory symptoms. These occur due to number of toxins (alpha & beta). Cardiovascular manifestations are more prominent with the sting of scorpion such as Hypertension, Myocarditis, Cardiac arrhythmias etc. [4]. Cardiovascular complications in scorpion stings: ECG abnormalities, Hypertension, Hypotension, Echocardiographic abnormalities, pulmonary edema, LVF, Cardiopulmonary arrest, LVF, left ventricular failure [5]. Systemic complications following scorpion sting, Autonomic storm, Dyselectrolytemia, Acute pancreatitis, Encephalopathy, Acute hepatic injury, Pulmonary edema, Acute renal failure, Metabolic acidosis, cerebrovascular accidents[6].

Local treatment of scorpion bite includes measures to reduce pain, immobilize the affected part, apply a topical anesthetic agent to decrease paresthesia, prophylaxis administration of tetanus, administration of systemic antibiotics, combination of beta-blockers with sympathetic alpha-blockers is most effective in reversing this venom-induced effect. Such as prazosin, nifedipine, nitroprusside, hydralazine, or angiotensin-converting enzyme inhibitors are used commonly. Antivenom is the treatment of choice after stabilization. Administration of atropine to counter venom-induced parasympathomimetic effects. The use of steroids to decrease shock and edema is of unproven benefit, care for newer scorpion antivenom as follows: Non-Centruroides and Centruroides antivenom [7].

CASE REPORT-

A 70 yr old female brought by relatives at night in casualty with history of bite over right foot great toe With patient giving history of bite by Red scorpion over right great toe at 11 pm in night. Patient presented after 3 to 4 hours of bite. At presentation patient complained of excruciating pain over bitten area which was followed by 2 to 3 episodes of profuse sweating. Patient was admitted in ICU. Patient's physical examination was done BP-170/100 mm of HG, Pulse-110/mins Respiratory rate -30/min Spo₂-94 off O₂, Systemic examination revealed bilateral infrascapular and infraxillary crepts on auscultation and rest of the examination was within normal limits. In previous history patient is known case of

hypertension for 2-3 years taking regular treatment for it. No history of any previous admission or any surgical illness in the past or any other comorbidity.

Lab investigations were sent which revealed BSL-83, Urea-59, Creatinine-1.6, Sodium-147, Potassium-4.5, Hb-10.5, Total leukocyte count-18500, Platelet count-3.60 lakhs, INR-1.1. Cardiac enzyme were positive with initial level of Troponin being 5 times more than normal value. Repeat level of Troponin in morning being 20 times more than normal showing rising trend of enzyme. ECG showed complete LBBB with left axis deviation. Urine report showed the presence of Myoglobin and Hemoglobin. Total level of CPK was mildly raised .Chest X-ray PA view and LFT were within normal limits. Patient was checked for infection such as Dengue, Leptospirosis, Malaria all came back negative. Blood culture was sent which was sterile after 5 days of incubation. 2D-ECHO findings were consistent with ECG findings showing paradoxical IVS with LBBB. Patient also has regional wall motion abnormality with antero-inferior Ventricular Septum (IVS) being akinetic. ECG on admission showed LBBB but subsequent ECG showed symmetric T wave inversion in V₁ to V₄ chest leads suggestive of Antero-Septal wall Myocardial Ischemic event.

Patient was treated with Positive Pressure Ventilation. Patient was given Tab. Prazosin 2.5 mg 12 hrly. Patient was given anticoagulant ,diuretics, antibiotics ,NSAID's, IV Fluids as further management. After 2 days urine routine was repeated which showed absence of Myoglobin. After 5 days of hospitalization patient took discharge because of financial restraints. Patient was discharged with dual anti-platelets, statins, diuretics, NSAIDS and patient was told to follow up in cardiology department for planning Coronary Angiography.

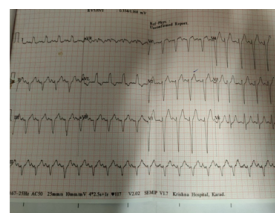


Figure 1-ECG ON ADMISSION

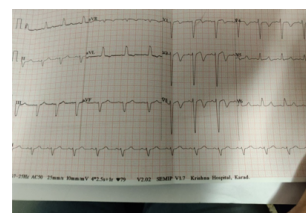


Figure 2-ECG AFTER 2 DAYS

DISCUSSION-

Scorpions are venomous arachnids belonging to the order Scorpionida, which are capable of inflicting fatal stings. They commonly inhabit the crevices of dwellings, under logs, paddy

Article History	Received	Accepted	Published
		12/09/2018	30/11/2018

*Corresponding Author Dr Akshay Kale
Junior Resident, Department Of Medicine, KIMS, Karad

husk, coconut and banana plantations. [8] Most of the species are nocturnal in habit, hiding under stones and seek cool and moist areas. Increased incidence was also noted in the month of October, which is the time to cut paddy. During this time, they do not get space to hide and come out of their crevices. [9]

Scorpion venom is a water-soluble, antigenic, heterogenous mixture, as demonstrated on electrophoresis studies. Soluble antigenic complex mixture of neurotoxin, cardiotoxin, nephrotoxin hemolysins, phosphodiesterases, phospholipase, hyaluronidases, histamine, and other chemicals. [5] This heterogeneity accounts for the variable patient reactions to the scorpion sting. [10] Scorpion venom contains a neurotoxin, haemolysins, agglutinins, haemorrhagins, leucocytolysins, coagulins, ferments, lecithin and cholesterolin. [11] The primary target of scorpion venom is voltage-dependent ion channels. Pathological lesions and electrocardiographic changes are due to sudden massive liberation of catecholamines in to circulation. Both sympathetic and parasympathetic twigs are stimulated.

The venom can cause myocardial damage by several pathogenetic mechanisms

Direct cardiotoxic effect of the venom- Causing toxic myocarditis by reduction of Na-K-ATPase and adrenergic myocarditis by releasing adrenaline and noradrenaline from neurons, ganglia, and adrenals, thereby increasing myocardial oxygen demand by direct inotropic and chronotropic effect on already compromised myocardial blood supply. [12]

Myocardial ischemia by coronary spasm -Release of vasoactive, inflammatory and thrombogenic peptides and amine constituents (histamine, serotonin, bradykinin, leukotrienes, thromboxane), which act on the coronary vasculature and induce coronary artery vasospasm and facilitate platelet aggregation as well as thrombosis. [13]

Anaphylactic reaction-Release of allergenic proteins causes anaphylactic shock leading to hypotension with vasodilation and decreased of intravascular volume with reduced myocardial perfusion. Scorpion venom inhibits angiotensin converting enzyme, resulting in accumulation of bradykinin, which is implicated in the development of pulmonary edema. [14]

It has been suggested that these circulating myocardial depressant substances have biochemical and pathogenic characteristics similar to those of a number of cytokines and particularly tumor necrosis factor. Tumor necrosis factor (TNF) could be involved in the cardiovascular effects caused by scorpion venom. [11,15] When the scorpion bites, venom is deposited in the skin deep to subcutaneous tissue, almost entire absorption of the venom from sting site would occur in 7-8 hours. 70% of maximum concentration of venom in the blood will be reached within 15 minutes and then time needed to reach maximum venom blood concentration is 101 ± 8 minutes in experimental animals, half-life of intravenously injected venom is between 4 to 7 minutes and takes 4.2 to 13.4 hours for elimination from blood [16]. The venom is a powerful arrhythmogenic agent. The actions of venom are inhibited by prazosin, atropine, propranolol and phentolamine [17].

Local reactions consist of itching, edema, and ecchymoses with burning pain. [18] It includes serious clinical sequelae like myocardial infarction, acute pulmonary oedema, cardiac arrhythmias, toxic myocarditis, cardiogenic shock etc. [19,20] Other reported features include oliguria due to acute renal failure, disseminated intravascular coagulation, priapism, pancreatitis, seizures and cerebral infarctions in children. [8-21, 22, 23, 24] Overstimulation of the sympathetic system increases blood levels of catecholamine's, resulting in a characteristic "adrenergic (autonomic) storm" which consists of cardiac (tachycardia, peripheral vasoconstriction, hypertension, diaphoresis), metabolic

(hyperthermia, hyperglycemia), urogenital (bladder dilatation, urinary retention, ejaculation in males), respiratory (bronchial dilatation, tachypnoea), and neuromuscular (mydriasis, tremor, agitation, convulsions) complications. [25]

The cardiovascular manifestations comprise successively of giddiness, bradycardia, a fall of body temperature; restlessness and tachycardia; and finally pulmonary edema. [26] Bahloul *et al.* examined the histopathology of two fatal myocarditis causes resulting from a scorpion bite, revealed a mixed picture of toxic myocarditis and coagulative myocytolysis, similar to catecholamine-induced cardiomyopathy. [27].

Most deaths occur during the first 24 hours after the sting and are secondary to respiratory or cardiovascular failure resulting from autonomic excitation. It leads to myocardial ischemia-induced myocardial hypoperfusion and to the direct effects of the toxin. Pulmonary edema may develop within 30 minutes to three hours after a sting due to myocardial dysfunction. Development of symptoms associated with pulmonary edema is variable but may be rapid. Tachypnea or intractable cough on admission could be signs of pulmonary evolving edema. In scorpion envenomation patients older than three years, the association of a respiratory rate of $> \text{or} = 30$ breaths/minute, agitation, sweating, or the presence of high plasma protein concentrations suggest the presence of pulmonary edema [28].

Successful management of scorpion sting includes tourniquette and specific antivenin [18]. Patients with pulmonary edema due to scorpion sting envenomation, all of them were successfully managed with the positive end-expiratory pressure (PEEP), cardiac support with inotropes and fluid balance [20]. Supportive therapies consist of conventional management of left ventricular failure and pulmonary edema. Hyper-oxygenation by positive pressure ventilation at high FiO₂ helped to reduce pulmonary hypertension. PEEP helped by alveolar recruitment and by shifting edema fluid away from the alveoli. Thus the first line of treatment was respiratory support with mechanical ventilation and inotropes.

In our patient finding mimicked acute myocardial infarction (including clinical symptoms, changes in ECG, elevated cardiac enzymes, regional wall motion abnormality in echocardiogram). Probably, coronary vasospasm associated with above-mentioned sequences (myocarditis, pulmonary edema) has precipitated acute myocardial infarction in our case.

Acute myocardial infarction occurs very rarely after an arthropod envenomation. There are few cases of acute myocardial infarction due to bee or scorpion bite reported in the literature. [29,30] Hence, it worth reporting this rare case. Initial presentation with frank ST segment elevation with pulmonary edema may be mistaken as acute myocardial infarction with pulmonary edema specially if the patient is having various risk factors for development of coronary event but similar situation in a young patient with no risks for coronary artery disease should make one to think of other causes of ST segment elevation with pulmonary edema.

CONCLUSION-

Scorpion bite is very common in rural Indian population most of the times being uncomplicated with local symptoms being predominant. But rare complication such as acute myocardial infarction, Pulmonary edema and Heart failure etc. being requires prompt medical attendance and treatment. Early diagnosis and treatment will be life saving.

REFERENCES-

1. Erfati P. Epidemiology, symptomatology and treatment of buthinae stings. In: Bettini S, editor. Arthropod Venoms: Hand Book of Experimental Pharmacology. New York: Springer Verlag; 1978. p.312-5.
2. Bisarya, B. N., Vasavada, J. P., Bhat, A., Nair, P. N. R. and Sharma, V.

- K: Hemiplegia and myocarditis following scorpion bite. *Indian Heart J*, 29:97-100, 1977.
3. Bawaskar HS. Personal communication, 1998.
 4. Bawaskar HS, Bawaskar PH. Indian red scorpion envenoming. *Indian J Pediatr* 1998;65(3):383-91.
 5. Raza M, Soomro et al, Cardiovascular Complications of Scorpion Stings And The Effects of Antivenom, *Journal of the Saudi Heart Association*, Vol. 10, No.1 , 1998
 6. SR Gadwalkar et al Bilateral Cerebellar Infarction: A Rare Complication of Scorpion Sting. *Japi*, vol. 54, July 2006
 7. David Cheng et al, *Scorpion Envenomation* May 16, 2013
 8. Singhal A, Mannan R, Rampal U. Epidemiology, Clinical Presentation and Final Outcome of Patients with Scorpion Bite. *J Clin. Diagn Res.* 2009 June; 3(3):1523-28.
 9. Patil SN. A Retrospective Analysis of a Rural Set Up Experience with Special Reference to Dobutamine in Prazosin-Resistant Scorpion Sting Cases. *J Assoc Physicians India.* 2009; 57:301-4.
 10. Chippaux JP, Goyffon M. Epidemiology of scorpionism: a global appraisal. *Acta Trop* 2008; 107:71-9.
 11. Modi, N. J.: "Modi's Textbook of Medical Jurisprudence and Toxicology." 24th Edition, N. M. Tripathi Pvt. Ltd., Princess Street, Bombay, 1977, p. 633
 12. Rahav G, Weiss AT. Scorpion sting-induced pulmonary edema. Scintigraphic evidence of cardiac dysfunction. *Chest* 1990;97:1478-80.
 13. Yang HP, Chen FC, Chen CC, Shen TY, Wu SP, Tseng YZ. Manifestations mimicking acute myocardial infarction after honeybee sting. *Acta Cardiol Sin* 2009;25:31-5.
 14. Bawaskar HS, Bawaskar PH. Management of scorpion sting. *Heart* 1999;82:253-
 15. Gueron, M., Adolph, R. J., Grupp, I. L., Gabel, M., Grupp, G. and Fowler, N. O.: Hemodynamic and myocardial consequences of scorpion venom. *Amer. J. Cardiol.*, 45: 979-986, 1980.
 16. Ismail M and Abd-el salam MA. Are the toxicological effects of scorpion envenomation related to tissue venom concentration? *Toxicon* 1988; 233-56.
 17. Ismail, M., El Asmar, M. F. and Osman, O. H. Pharmacological studies with scorpion venom; evidence for the presence of histamine. *Toxicon.*, 13:49-56. 1975.
 18. Wallace JF. Disorders caused by venoms, bites and stings. In: Isselbacher KJ, Adams RD, Braunwald E, Petersdorf RG, Wilson JD, editors. *Harrison's Principles of Internal Medicine.* 9th ed. Johannesburg, London, Tokyo, etc.: McGraw-Hill International Book Co.; 1980. p. 924-
 19. Maheshwari M, Tanwar CP. Scorpion Bite Induced Myocardial Damage and Pulmonary Edema. *Heart Views.* 2012; 13(3):16-8.
 20. Bhadani UK, Tripathi M, Sharma S, Pandey R. Scorpion Sting Envenomation Presenting with Pulmonary Edema in Adults: A Report of Seven Cases from Nepal. *Indian J Med Sci.* 2006; 60(1):19-23.
 21. Kumar L, Naik SK, Agarwal SS, Bastia BK. Autopsy Diagnosis of a Death due to Scorpion Stinging – A Case Report. *J Forensic Leg Med.* 2012; 19:494–6.
 22. Hahn IH. Arthropods. In: Nelson LS, Lewin NA, Howland MA, Hoffman RS, Goldfrank LR, Flomenbaum NE, eds. *Goldfrank's Toxicologic Emergencies.* New Delhi, McGraw Hill Medical; 2011:1561-81.
 23. Rajasekhar D, Mohan A. Clinical and Echocardiographic Findings in Patients with Myocardial Toxicity due to Scorpion Sting. *Natl Med J India.* 2004; 17(6):307-9.
 24. Bawaskar HS, Bawaskar PH. Clinical Profile of Severe Scorpion Envenomation in Children at Rural Setting. *Indian Pediatr.* 2003; 40:1072-75.
 25. Chippaux JP. Emerging Options for the Management of Scorpion Stings. *Drug Des Dev Therapy.* 2012; 6:165–73.
 26. Mundle PM. Pulmonary edema following scorpion stings. *Br Med J* 1961; 1:1042.
 27. Bahloul M, Kallel H, Rekik N, Ben Hamida C, Chelly H, Bouaziz M. Cardiovascular dysfunction following severe scorpion envenomation. Mechanisms and pathophysiology.
 28. BOUAZIZ, M.; BAHLOUL, M.; HERGAFI, L. et al. - Factors associated with pulmonary edema in severe scorpion sting patients: a multivariate analysis of 428 cases. *Clin. Toxicol. (Phila.)*, 44:293-300, 2006.
 29. Levine HD. Acute myocardial infarction following wasp sting. Report of two cases and critical survey of the literature. *Am Heart J* 1976; 91:365-74.
 30. Wagdi P, Mehan VK, Bürgi H, Salzmann C. Acute myocardial infarction after wasp stings in a patient with normal coronary arteries. *Am Heart J* 1994; 128:820-3.