



EVALUATION OF THE VARIANTS OF BILIARY TREE BY MRCP IN PATIENTS WITH PRIMARY HEPATO-BILIARY DISEASES AND OTHER ABDOMINOPELVIC CONDITIONS

Ingole Dilip

M.B.B.S., Resident (MD Radiodiagnosis), Department of Radiodiagnosis and Imaging, Armed Forces Medical College, Pune.

Grewal D S

MD (Radiodiagnosis), Department of Radiodiagnosis and Imaging, Armed Forces Medical College.

Chatterjee Samar

MD (Radiodiagnosis), Department of Radiodiagnosis and Imaging, Armed Forces Medical College.

C M Sreedhar

MD (Radiodiagnosis), Department of Radiodiagnosis and Imaging, Armed Forces Medical College.

ABSTRACT

Introduction: Magnetic resonance cholangiopancreatography (MRCP) is an excellent non-invasive imaging technique for the visualization of the detailed biliary anatomy.

Methodology: 200 patients with primary hepatobiliary diseases and 200 patients referred for other abdominopelvic conditions with were evaluated by MRCP.

Results: There was no statistically significant difference in these two groups in anatomic variation in hepatobiliary (p value=0.18) and cystic duct (p value=0.81)

Conclusion: MRCP helps in pre-operative evaluation of the bile ducts, cystic ducts so as to avoid the possible operative complications related to variant anatomy.

KEY WORDS : MRCP, hepatobiliary diseases, anatomic variations

Introduction:

Magnetic resonance cholangiopancreatography (MRCP) is a special type of magnetic resonance imaging (MRI) examination which provides the detailed imaging evaluation of the hepatobiliary and pancreatic systems. Magnetic resonance imaging (MRI) is a noninvasive investigation which clinicians use to diagnose medical conditions.¹

The MRCP is the investigation of choice for the study of the hepatobiliary system which includes the biliary calculi, tumors, inflammation or infection. It is useful to evaluate the patients with pancreatitis for the detection of the underlying cause. It is also useful in diagnosing the unexplained abdominal pain and also provides a less invasive alternative to endoscopic retrograde cholangiopancreatography (ERCP).¹ It has replaced the Endoscopic Retrograde Cholangiopancreatography (ERCP) as a modality of choice to study the pancreatobiliary tract.²

High resolution cross-sectional Two-dimensional (2D) and three-dimensional (3D) projection images gives an excellent detailed anatomy of biliary tree. We commonly get with the anatomic variations of the Intra and extra-hepatic biliary tree. There are different patterns of the variations of intra-hepatic biliary tree and of the cystic duct anatomy. Though these anatomic variations of biliary tree are not pathological per se, but these are of clinical significance in specific situations like hepato-biliary or gall bladder interventional procedures and surgeries.³

This study was conducted to determine such anatomic variations of both intra-hepatic and extra-hepatic biliary tree on MRCP.

Objectives:

1. To study the anatomic variations of intra-hepatic and extra-hepatic biliary tree in patients with the primary diseases of the hepato-biliary system

2. To study the anatomic variations of intra-hepatic and extra-hepatic biliary tree in patients with other abdominal and pelvic organs diseases

MATERIAL AND METHODS

Study design:

The present study was observational study undertaken to study the anatomic variations of intra-hepatic and extra-hepatic biliary tree on MRCP.

Study setting:

The study was conducted in department of Radiology of a tertiary care hospital setting.

Study period:

The present study period was from November 2016 to October 2018.

Study population:

The study population was patients presenting to the department of Radiology for MRCP, MRI abdomen and MRI pelvis.

Sample size:

A total sample size of 400 patients presenting to the department of Radiology for MRCP, MRI abdomen and MRI pelvis was included in the study population.

Sample size estimation:

The variations in normal biliary tree anatomy with 95% confidence interval and precision of 5% variance around true variation with prevalence of anatomic variations of biliary tract. i.e. 42% (Normal biliary anatomy is seen in 58% population).⁴

$$n = \frac{4pq}{L^2}$$

Article History	Submitted	Accepted	Published
	19/08/2019	03/10/2019	20/11/2019
*Corresponding Author Dr D S Grewal			
Professor, Dept of Radiodiagnosis, Armed Forces Medical College, Solapur Road, Pune drdsgrewal@gmail.com			

Where, n = Sample size
p = Prevalence=42
q = (1 - p)
L=Absolute error
p=42%=0.42
q = (1 - p)=1 - 0.42=0.58
L = 5%

So,

$$n = \frac{4(0.42)(0.58)}{(0.05)^2} = 389$$

Hence a total sample size of 400 patients was the study population and underwent MRCP. 50% of the study population was comprised of the patients with primary diseases hepatobiliary system and the remaining 50% was the patients referred for other abdominal and pelvic MRI studies. All patients underwent MRCP study with standard protocol.

Study groups:

The patients were divided into 2 groups:
Group B Patients with primary diseases of hepatobiliary system
Group C: Patients referred for other abdominal and pelvic MRI studies.

Each of the groups contains 200 patients.

Selection criteria:

Inclusion criteria:

All patients referred from various departments for MRCP, MRI abdomen and MRI pelvis

Exclusion criteria:

Lack of adequate quality of magnetic resonance imaging
Distortion of biliary tree due to tumour or any space occupying lesion or any surgery of biliary tree.

Ethical consideration:

The study was approved by the Ethical Committee of the Medical College.

METHODOLOGY

MRCP Protocol

All patients must fast for 6 hours prior to examination to reduce fluid secretions within the stomach and duodenum, reduce bowel peristalsis and promote gallbladder distension.

MRCP procedure was performed with Magnetom Symphony 1.5 Tesla. With coronal and axial T2-weighted (T2W) single- shot fast spin-echo (FSE) sequence, axial respiratory-triggered fat-suppressed T2W FSE sequence.

Data collection:

All patients in fulfilling inclusion criteria were selected. Informed consent was taken from the patients. The selected subjects were assessed for MRCP. Data was collected, images were evaluated in picture archiving communication system (PACS) and variations intrahepatic and extrahepatic biliary radicles were studied in both the groups.

Statistical analysis

All data analysis had been done by using SPSS (version 22) for windows. The initial measures of each group were compared with the final measures of the study period and compared by using chi square test.

Results:

Table No. 1: Anatomy of the intra-hepatic biliary tree in group B & C patients

Biliary anatomy (Type)	Interpretations	No. of Patients (%) Group B n=200	No. of Patients (%) Group C n=200
Type I (Typical or	RPSD enters RASD medially to form RHD	128 (64)	114 (57)
Type II	Trifurcation: Confluence of RASD, RPSD and LHD into the CHD	27 (13.5)	18 (9)
Type III	Anomalous drainage of RPSD	44 (22) (a+b+c)	65 (32.5) (a+b+c)
	a- RPSD entering into LHD (crossover anomaly)	21	38
	b- RPSD into CHD	23	27
	c- RPSD into cystic duct	0	0
Type IV	Aberrant drainage of RHD into the cystic duct	01 (0.5)	03 (1.5)
Type V	Accessory right hepatic duct	0 (0)	0 (0)
Type VI	Segments II and III duct draining	0 (0)	0 (0)
Type VII	Other unclassified variations	0 (0)	0 (0)

$\chi^2=2.05, d.f=1, p=0.18$
Table no. 1 shows that total anatomical variations in intrahepatic biliary tree is seen 72 (36%) and 86 (43%) in group B and C patients respectively. There is no statistically significant difference between the two groups.

Table No. 2: Distribution according to anatomic variations of cystic duct in Group B & C patients

Anatomic variations (Type)	No. of Patients (%) Group B n=200	No. of Patients (%) Group C n=200
Type A: low insertion into the distal third of CBD	17 (8.5)	21 (10.5)
Type B: Medial insertion of cystic duct into CBD	27 (13.5)	22 (11)
Type C: Parallel course with common hepatic duct	01 (0.5)	00 (0)
Type D: High insertion of cystic duct into common hepatic duct	00 (0)	00 (0)
Type E: Cystic duct draining to right hepatic duct	00 (0)	00 (0)
Type F: Cholecystohepatic duct	00 (0)	00 (0)
Type G: Cystic malformations of cystic duct	00 (0)	00 (0)
Type H: Other unclassified variations	00 (0)	00 (0)
No Anatomical Variation in cystic duct	155 (77.5)	157 (78.5)

$\chi^2=0.06, d.f=1, p=0.81$
Table no. 2 shows that total anatomical variations in cystic duct is seen 45 (22.5%) and 43 (21.5%) in group B and C patients respectively. There is no statistically significant difference between the two groups.

Discussion:

The indication for MRCP among group B patients showed that the majority of patients had indication of Cholelithiasis (31.5%), followed by Obstructive jaundice (28%), Choledocholithiasis (11.5%), Acute cholecystitis (6.5%), Acute pancreatitis (5.5%), Liver mass (3.5%), Pancreatic mass (2.5%), Chronic pancreatitis (1.5%), and Acute cholangitis (1.5%). In a study

by Alaaddin Nayman et al⁵ on MRCP evaluation of intrahepatic bile duct variations observed major indication for MRCP was Cholelithiasis (preoperative assessment) (29.2%) followed by obstructive jaundice (27.6%).

In the present study, anatomy of the intra-hepatic biliary tree among all patients (Group B and C) showed that the majority of patients had normal anatomy (Type I) (60.5%). The variation of intra-hepatic biliary tree of anomalous drainage of RPSD was seen in 27.25% patients (of which RPSD entering into LHD i.e. type IIIa was 14.25% and RPSD into CHD i.e. type IIIb in 13%), trifurcation (Type II) was seen in 11.25% and the aberrant drainage of RHD into the cystic duct was seen in 4 (1%) patients.

The anatomy of the intra-hepatic biliary tree among group B patients showed majority of patients had normal anatomy (Type I) (64%). The variation of intra-hepatic biliary tree of anomalous drainage of RPSD (Type III) seen in 22% patients (of which RPSD entering into LHD i.e. type IIIa was 10.5% and RPSD into CHD i.e. type IIIb in 11.5%), trifurcation (Type II) was seen in 13.5% and the aberrant drainage of RHD into the cystic duct was seen in 1 (0.5%) patient.

The anatomy of the intra-hepatic biliary tree among group C patients showed majority of patients had normal anatomy (Type I) (57%). The variation of intra-hepatic biliary tree of anomalous drainage of RPSD (Type III) seen in 32.5% patients (of which RPSD entering into LHD i.e. type IIIa was 19.0% and RPSD into CHD i.e. type IIIb in 13.5%), trifurcation (Type II) was seen in 9.0% and the aberrant drainage of RHD into the cystic duct was seen in 3 (1.5%) patients.

The majority of all study population (Group B and C) had normal anatomy i.e. absent anatomic variations (60.5%). while variation of intra-hepatic biliary tree was present seen in 158 (39.5%) patients.

Similar findings were seen in a study by Binit Sureka, et al³ on Magnetic resonance cholangiographic evaluation of intrahepatic and extrahepatic bile duct variations that, hepatic bile duct variation with anomalous drainage of RPSD (Type III) in 17% patients followed trifurcation (Type II) (5%).

In a study by Alaaddin Nayman et al⁵ on MRCP evaluation of intrahepatic bile duct variations observed intrahepatic bile duct anatomy Type I (62%) Type II (9%) Type III (11%) and Type IV (7%)

The anatomic variations of cystic duct were seen in 22 % all patients (both group B and C), of which majority of patients had medial insertion of cystic duct into CBD (Type B) (12.25%) followed by low insertion into the distal third of CBD (9.5%) and Parallel course with Common hepatic duct (Type C) (0.25%) Similarly, in Group B the majority of patients had medial insertion of cystic duct into CBD (Type B) (13.5%) followed by low insertion into the distal third of CBD (8.5%) and Parallel course with Common hepatic duct (Type C) (0.5%)

In group C, majority of patients had medial insertion of cystic duct into CBD (Type B) (11%) followed by low insertion into the distal third of CBD (10.5%).

Similar findings were seen in a study by Binit Sureka, et al³ where majority of patients had medial insertion of cystic duct into CBD (Type B) (10-17%) followed by low insertion into the distal third of CBD (9%) and Parallel course with Common hepatic duct (Type C) (1.5%)

Radha Sarawagi et al⁶ demonstrated the imaging features of CD and its variants using MRCP observed among 198 patients who underwent MRCP due to different indications normal lateral insertion of CD at middle third of common hepatic duct was seen in 51% of cases. Medial insertion was seen in 16% of cases, of which 4% were low medial insertions. Low insertion of CD was noted in 9% of cases. Parallel course of CD was present in 7.5% of cases. High

insertion was noted in 6% and short CD in 1% of cases. In 1 case, CD was draining into right hepatic duct.

The anatomic variations of intra-hepatic biliary tree in the patients without the diseases of the hepatobiliary system (Group C) were more (43%) as compared to the variation of intra-hepatic biliary tree in patients with the primary diseases of the hepatobiliary system (Group B) i.e. 36%. However there was no statistically significant difference between the two groups. (P=0.18)

The anatomic variations of extra-hepatic biliary tree in the patients with the primary diseases of the hepatobiliary system i.e. Group B were more (22.5%) as compared to the variations of extra-hepatic biliary tree in the patients without the diseases of the hepatobiliary system Group C (21.5%). However there was no statistically significant difference between the two groups. (P=0.81)

In a study by K.A.H. Talpurt et al⁷ classical anatomy of cystic duct joining the CHD at its middle third from lateral aspect is seen in 58%–75% of cases.

In a study by H. Onderet al⁸ medial insertion of cystic duct was reported in 10–18% of cases and low insertion of cystic duct (LICD) was reported in 8 to 11% of cases.

MRCP is a noninvasive imaging modality which optimally images the bile ducts and cystic duct. MRCP provides important information regarding cystic duct anatomy and has a significant safeguarding effect on laparoscopic cholecystectomy. Prior to laparoscopic surgery, the knowledge of the cystic duct anatomy and its variants helps in proper interpretation of disease process and avoids iatrogenic injuries. In medicolegal purposes, preoperative documentation of bile duct anatomy may also help.⁹

It is important to recognize the anatomical variations of cystic ducts which are common. MRCP begin an excellent imaging modality for the demonstration of cystic duct anatomy and its variations, which not only helps in proper interpretation of the disease process but also provides a roadmap before any percutaneous, endoscopic, and surgical interventions.

Recently, percutaneous transcholecystic biliary interventions are being performed through the cystic duct, pre-surgical knowledge of the cystic duct anatomy and its variations helps in planning the procedure and helps to avoid the possible surgical complications.

Conclusions:

In all study population, normal biliary anatomy was seen. The anatomic variations of intra-hepatic biliary tree were seen 39.5% and those of cystic ducts were 22%.

MRCP being non-invasive imaging modality, can optimally image the bile ducts and cystic duct.

With the accurate demonstration of the bile ducts, cystic ducts with their anatomic variation, MRCP helps in pre-operative evaluation. It avoids the possible operative complications related to this variant anatomy.

Limitations: In our study, we could not get the uncommon anatomic variations of intrahepatic biliary tree (Type V, VI, and VII) and that of cystic duct (Types D, E, F, G, and H), possibly due to our small sample size in comparison with the reference studies.

Conflict of interest: None

Funding: None

Acknowledgement:

REPRESENTATIVE STUDY IMAGES

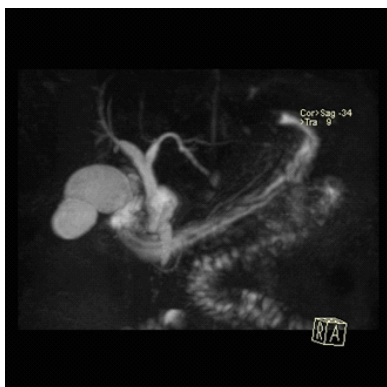

Image 1: Normal anatomy (Type I/ typical): Coronal MRCP images showing joining of right posterior sectoral duct (RPSD) joining right anterior sectoral duct (RASD) posteriorly and medially (arrow).

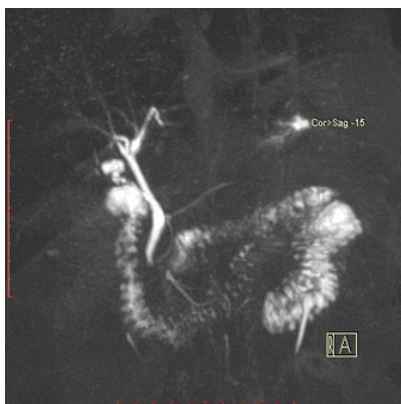

Image 2: Type II anatomy (Trifurcation) - Confluence of RASD, RPSD and LHD to form CHD.

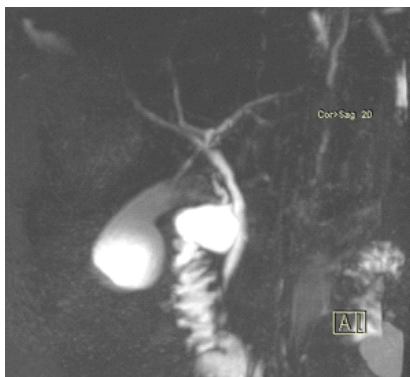

Image 3: Type IIIa- Anomalous drainage of right posterior sectoral duct (RPSD) (arrow) entering into left hepatic duct (LHD) (Crossover anomaly)

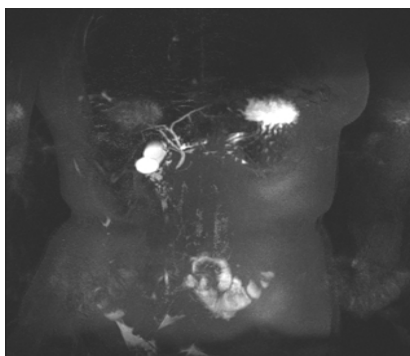


Image 4: Type IIIb anatomy- Right posterior sectoral duct (arrow) entering into common hepatic duct.

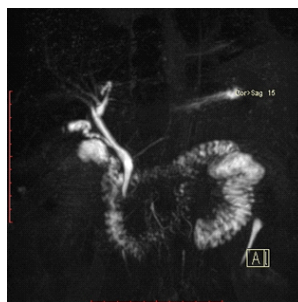

Image- 5

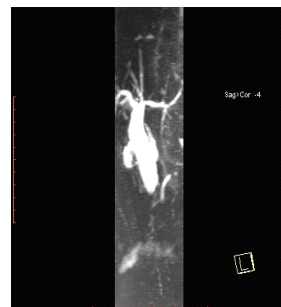


Image -6

Images 5 and 6: Medial Insertion of cystic duct (Type B)

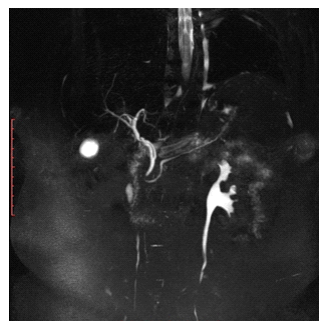


Image 7: Trifurcation (type II) and low insertion of cystic duct (arrow) into distal 3rd CBD (type A)

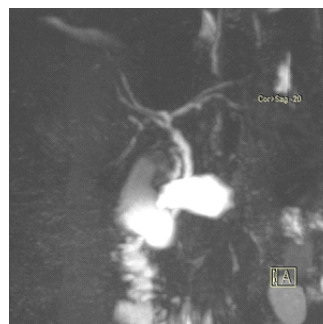

Image 8: Lateral insertion of cystic duct

References:

1. Magnetic Resonance Cholangiopancreatography. Radiology Info. 2017;1-8.
2. Gupta RT, Brady CM, Lotz J, Boll DT, Merkle EM. Dynamic MR imaging of the biliary system using hepatocyte-specific contrast agents. AJR Am J Roentgenol 2010;195:405-13.
3. Sureka B, Bansal K, Patidar Y, Arora A. Magnetic resonance cholangiographic evaluation of intrahepatic and extrahepatic bile duct variations. Indian J Radiol Imaging 2016; 26:22-32.
4. Minutoli F, Naso S, Visalli C, Iannelli D, Silipigni S, Pitrone A, et al. A new variant of cholecystohepatic duct: MR cholangiography demonstration. SurgRadiolAnat 2014.3 (4):17-23.
5. Nayman A, Özbek O, Erol S, Karakuş H, Kaya HE. Magnetic resonance cholangiopancreatography evaluation of intrahepatic bile duct variations with updated classification. Diagn Interv Radiol. 2016; 22(6):489-494.
6. Radha Sarawagi, Shyam Sundar, Sanjeev K. Gupta, and Sameer Raghuwanshi. Anatomical Variations of Cystic Ducts in Magnetic Resonance Cholangiopancreatography and Clinical Implications. Radiology Research and Practice. 2016, Article ID 3021484:1-6.
7. K. A. H. Talpur, A. A. Laghari, S. A. Yousfani, A. M. Malik, A. I. Memon, and S. A. Khan, "Anatomical variations and congenital anomalies of extra hepatic biliary system encountered during laparoscopic cholecystectomy," Journal of the Pakistan Medical Association. 2010; 60 (2):89-93.

8. H. Onder, M. S. Ozdemir, G. Tekbas, F. Ekici, H. Gum us, and A. Bilici, "3-T MRI of the biliary tract variations," *Surgical and Radiologic Anatomy*. 2013; 35 (2):161–167.
9. Wallner BK, Schumacher KA, Weidenmaier W, Friedrich JM. Dilated biliary tract: evaluation with MR cholangiography with a T2-weighted contrast-enhanced fast sequence. *Radiology* 1991; 181:805-8.