



A CASE OF AUTOIMMUNE ENCEPHALITIS

Gaurav Pathania

Resident, Dept of Medicine Department of Medicine, Armed Forces Medical College, Pune

Saurabh Mohakuda

MD Medicine, Dept of Medicine Department of Medicine, Armed Forces Medical College, Pune

Yadvendra Sirohi

MD Medicine, DM Neurology, Dept of Medicine Department of Medicine, Armed Forces Medical College, Pune

Elsadig Yousif Mohamed

Associate Professor of Community Medicine, College of Medicine, Majmaah University, Saudi Arabia

Sawsan Mustafa Abdalla

Associate Professor of Community Medicine, College of Medicine, Majmaah University, Saudi Arabia

Omer Mohammed Mohammed Taha

Assistant professor of Internal Medicine, College of Medicine, Majmaah University, Saudi Arabia

Wala Ali Mohamed Musa

Assistant professor of Internal Medicine, College of Medicine, Majmaah University, Saudi Arabia

ABSTRACT

Autoimmune encephalitis is a potentially fatal autoimmune syndrome. Here we report a case of N-methyl-D-aspartate receptor (NMDAR) antibody encephalitis in which there is antibody production against the NMDAR causing profound dysregulation of neurotransmission. The syndrome is frequently associated with ovarian teratomas and women are disproportionately affected. Patients most often present with a constellation of neuropsychiatric signs and symptoms,

KEY WORDS : Biomarkers Neural Plasticity.

including memory loss, hallucinations, and decreased level of consciousness. This condition is lethal if left untreated. Immunotherapy and surgical resection of the culprit malignancy often results in the rapid resolution of symptoms. Acute encephalitis is a debilitating neurological disorder that develops as a rapidly progressive encephalopathy (usually in less than 6 weeks) caused by brain inflammation. Various syndromes of autoimmune encephalitis have been described with advent of newer biomarkers. The clinical syndrome comprises of cognitive disturbances, mood/personality changes, seizures and movement disorders. Annual incidence 1/100000 in northern Europe. India has not been studied separately.

2. Etiology

Anti-NMDAR encephalitis is a relatively rare diagnosis with just a few hundred cases reported in the literature but its true prevalence, especially in individuals with purely psychiatric manifestations, is yet to be determined as a large majority present to a psychiatrist first . NMDARs play a central role in synaptic transmission helping to modulate human memory, cognition, and learning and have been implicated in neural plasticity . Activity of the NMDAR is affected not only by several exogenous substances, including PCP, ketamine, and ethanol, but also endogenous brain-immune interactions that can have tremendous clinical consequence.

The structure of the NMDAR is composed primarily of ubiquitous

NR1 and NR2 subunits . The antibodies in anti-NMDAR encephalitis are directed against an epitope found on the NR1 subunit primarily in the frontotemporal and hippocampal regions likely owing to the high density of these receptors in these regions. This geographic pattern helps explain common psychiatric signs and symptoms seen in this disease, including decreased cognition and personality changes.

Frequently, anti-NMDAR antibody formation has been associated with the presence of certain malignancies, but the initiating event triggering antibody production has yet to be identified. In the literature, ovarian teratomas accounted for 94% of all neoplasms responsible for the formation of anti-NMDAR encephalitis, with clinical improvement after tumour removal .

3. Diagnosis

The psychiatric manifestation of anti-NMDAR encephalitis syndrome is preceded by a nonspecific prodromal stage that can include headaches, low-grade fevers, diarrhea, or upper respiratory infection symptoms . This is followed by prominent psychiatric changes like anxiety, paranoia, mania, hyper-religiosity, delusions, and hallucinations that initiate within 2 weeks. Short-term memory loss evaluation is hindered by accompanying language deficits from echolalia to mutism .

Neuromotor dysfunction with ataxia and choreiform movements and autonomic instability may also occur as the disease progresses.

Article History	Submitted	Accepted	Published
	02/09/2019	27/10/2019	20/11/2019

***Corresponding Author** Dr Gaurav Pathania
Resident, Dept of Medicine Department of Medicine, Armed Forces Medical College, Pune

Complex seizures present relatively early but overlap between epileptiform movements and orofacial dyskinesias may present a clinical dilemma in proper identification. Furthermore, overlap of the syndromic symptoms with that of schizophrenia often leads to misdiagnosis and inappropriate treatments.

Brain MRI has been reportedly negative in up to 50–70% of patients. When irregularities are seen, it is often subtle T2 or FLAIR sequence hyperintensities in the hippocampal, frontobasal, insular, or basal ganglia regions. EEG may show abnormal slowing, but is nonspecific in 90% of patients and there is no role for brain biopsy in diagnosis.

Current diagnosis is based upon finding anti-NMDAR antibodies in the CSF or serum. CSF studies show lymphocytic pleocytosis and normal to mild elevation of protein. Oligoclonal bands may be present in 60% of patients. Although there is controversy between testing for serum or CSF antibody titers, CSF titers generally appear to correlate with disease activity. The CSF antibody has been found to be more sensitive but there are still some explanations for why one might find a falsely negative result. This may include smaller quantities of antibodies produced, antigen denaturation during tissue-based immunofixation and variability between human and mouse epitopes used in analysis. In our patient, serum titers were negative as were CSF antibody titers, which is atypical, but given her characteristic neuropsychiatric dysfunction with rapid symptom resolution after ovarian teratoma removal, a presumptive diagnosis of anti-NMDAR encephalitis fit the bill.

4. Treatment

Immunomodulation and neoplasm removal targeting both symptomatic and causal factors are mainstays of treatment. Immunotherapy such as with steroids, plasmapheresis and IVIG helps reduce antibody titres. Tumour removal in those with identifiable lesions leads to rapid clinical improvement. Second-line therapy consists of Rituximab or cyclophosphamide. Benzodiazepines and antipsychotics round out the pharmacotherapies employed in the treatment of seizures, psychosis and behavioural dysfunction. Recovery from illness following treatment is generally good with up to 75% of patients achieving full recovery or left with minimal residual deficits. Severe disability may result in the remaining 25% with mortality rates of 4–7%. Reported relapse rates range between 12% and 24%, more often in those without teratoma. The largest cohort study to date of 577 patients reported 53% recovery based on the modified Rankin Scale, and 97% of those who improved had good outcome at 24 months. Prognosis is guarded and disease can often be lethal with irreversible damage to cortical regions such as the hippocampus in those who experience delay in identification and treatment. Independent predictors of good clinical outcome include time to identification and treatment, admission not requiring ICU care, and lesser initial symptomatology(4).

5. Case summary

34 years old female pilot presented with complaints of fever of 12 days duration which was moderate to high grade, remittent, associated with chills and rigors with history of pain abdomen & burning sensation in urine. She took some oral antibiotics which resulted in defervescence of fever for 3–4 days. However the lady was brought back to the military medical facility with recurrence of fever after 3 days associated with behavioural abnormality in the form of crying, shouting, pervasive ideas of dying and seeing god of 2 days duration. There was a preceding history of severe headache with subtle behavioural changes for which the patient had to be taken off from her flying duty 2 weeks prior to presentation as was brought out by the husband.

Clinical examination was s/o dysautonomia (postural hypotension) and MMSE 22 with no other neurological deficit.

Investigations revealed a normal haematological and biochemical

profile. CSF studies were suggestive of pleocytosis (WBC: 20/HPF) with negative neuroviral markers. Autoimmune workup revealed NMDA receptor to be positive. Tumour markers were negative and MRI Brain was normal.

The patient was admitted to the ICU and started on intravenous antibiotics on suspicion of a meningoencephalitis while awaiting the autoimmune profile of the patient. She was administered antipsychotic drugs in view of her violent behavior. On ascertaining a diagnosis of Autoimmune encephalitis, she was initiated on pulse steroids followed up with intravenous immunoglobulin following an inadequate response.

In view of partial response, we managed her with intravenous Rituximab and Mycophenolate mofetil and the intravenous immunoglobulin was repeated on Day 37 of illness. The course was complicated with her developing catatonic excitation with antipsychotic drugs which were substituted by benzodiazepines. Tab Clonidine 0.05mg TID was added in view of dysautonomia and she was given tab divalproex 75mg BD as seizure precaution. Repeated imaging turned out to be normal.

The patient showed clinical improvement in form decreased agitation, decreased requirement of sedation, episode of eye contact with response.

Presently the patient can walk without support, recognize relatives, has normal meaningful conversation with intermittent pseudo philosophical ideas and ideas of grandiosity.

6. Discussion

Autoimmune encephalitis is a difficult clinical diagnosis due to the similarities in the clinical, imaging and laboratory findings of many forms of autoimmune and infectious encephalitis. Clinical suspicion is the key to early diagnosis as facilities for autoimmune profiling are not available at all the centers across the country.

Picture 1 & 2 showing the patient's MRI as against a characteristic imaging seen in Autoimmune Encephalitis

Figure 1

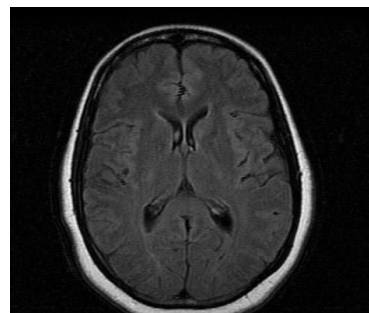
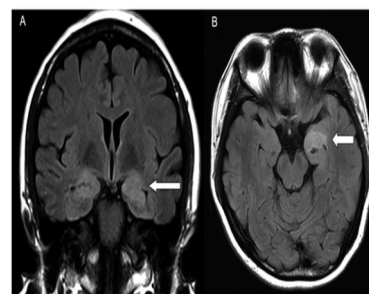


Figure 2



References

1. Kayser M, Dalmau J. Anti-NMDA Receptor Encephalitis in Psychiatry. *Curr Psychiatry Rev.* 2014;7(3):189–93.
2. Wong D, Fries B. Anti-NMDAR encephalitis, a mimicker of acute

- infectious encephalitis and a review of the literature. IDCases [Internet]. 2014;1(4):66–7. Available from: <http://dx.doi.org/10.1016/j.idcr.2014.08.003>
3. Dalmau J. Clinical experience and laboratory investigations in patients with anti-NMDAR encephalitis Prof Josep Dalmau , Department of Neuroscience , University of Pennsylvania School of Medicine (Prof R Balice-Gordon , PhD), Philadelphia, PA, USA The syndrome. *Lancet Neurol*. 2011;10(1):2–3.
 4. Titulaer, M. J., McCracken, L., Gabilondo, I., Armangué, T., Glaser, C., Izuka, T., Honig, L. S., Benseler, S. M., Kawachi, I., Martinez-Hernandez, E., Aguilar, E., Gresa-Arribas, N., Ryan-Flanagan, N., Torrents, A., Saiz, A., Rosenfeld, M. R., Balice-Gordon, R., Graus, F., ... Dalmau, J. (2013). Treatment and prognostic factors for long-term outcome in patients with anti-NMDA receptor encephalitis: an observational cohort study. *The Lancet. Neurology*, 12(2), 157-65.