



POSTURAL INTERCOSTAL HERNIATION OF A SKELETAL MUSCLE HEMANGIOMA

Sanjeev Kumar Verma

(MD) Department Of Respiratory Medicine, King George's Medical University, UP, Lucknow

Dr. Richa Tyagi*

(MD) Department of Respiratory Medicine, King George's Medical University, UP, Lucknow.*Corresponding Author Email id: dr.richapulmo@gmail.com

Dr. Rajiv Garg

(MD) Department of Respiratory Medicine, King George's Medical University, UP, Lucknow

Dr. Anand Srivastava

(MD) Department of Respiratory Medicine, King George's Medical University, UP, Lucknow

ABSTRACT

A young Indian female presented to us with a reducible swelling in anterior chest wall which appeared only on forward flexion. The postural association made it a unique presentation. The reducible nature made us suspect lung herniation, however, clinical examination made it unlikely. Subsequent imaging revealed spontaneous intercostal herniation of a skeletal muscle hemangioma, which is a rare occurrence. The patient was explained the nature of the pathology and managed conservatively. To our knowledge, this is the first case of its kind.

KEY WORDS : hernia; reducible swelling; chest wall tumors

INTRODUCTION

A reducible swelling arising from an intercostal space is an infrequent occurrence and the likely diagnosis is herniation of lung. It usually occurs secondary to weakness in the overlying chest wall, which could be traumatic or congenital. Several cases have been reported in literature.¹⁻⁴ However, postural herniation of skeletal muscle hemangioma through an intercostal space has not been described. Skeletal muscle hemangiomas are rare and usually occur secondary to trauma. They present as unexplained intermittent dull aching pain of long duration and swelling. The overlying skin appears normal or could have a bluish discoloration or a scar in case of antecedent trauma.^{5,6} Unlike some varieties of cutaneous hemangiomas, these do not regress spontaneously. We are presenting a case of hemangioma herniating through intercostal space in left parasternal region only on bending forwards which is an atypical presentation.

CASE PRESENTATION

A twenty-five year old female presented to us complaining of appearance of a bulge in the chest wall anteriorly on bending forwards. She noticed it for the first time about two months back when the bulge used to be very small. Now gradually it had become more obvious. It was associated with mild dull aching type of non-radiating pain. The patient had no other complain and denied any medical/surgical history or history of trauma to the chest wall.

CLINICAL FINDINGS

We asked her to demonstrate the emergence of bulge. She bent forward for about twenty seconds and a swelling appeared in left parasternal region.

On inspection an ill-defined swelling appeared in left parasternal region 7 cm below the medial end of left clavicle, measuring about 1.5 cm in diameter. The overlying skin appeared normal. [Figure I] There was no association with respiratory movements. On palpation, it was firm, tender, non-fluctuant and local temperature was normal. Resonant note was heard on percussion. On auscultation, vesicular breath sounds were heard as in other lung areas. It reduced spontaneously within twenty seconds. Owing to the reducible nature of the swelling, we asked her to perform valsalva maneuver and to cough. However, it did not reappear.

Investigations:

Chest radiograph (postero-anterior view) was normal. High resolution ultrasonography (HR-USG) of the swelling in bent forward posture showed a small defect in the anterior chest wall measuring about 5 mm with protrusion of an oval shaped hypoechoic shadow measuring 18 x 7 mm.[Figure II] Contrast enhanced computed tomography (CECT) scan of the thorax revealed an intensely enhancing nodular lobulated soft tissue lesion measuring about 12 x 9 mm in left parasternal region deep to pectoralis major.[Figure III]

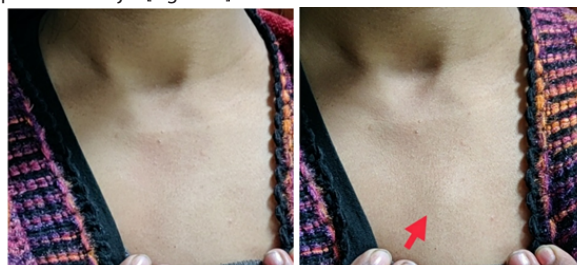
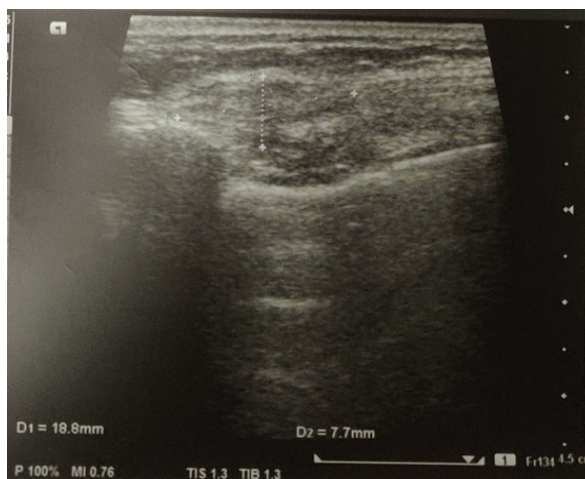

Figure 1: Appearance of a bulge in left parasternal region on bending forwards for about 20 seconds (marked with red arrow).



***Corresponding Author Dr. Richa Tyagi**

(MD) Department of Respiratory Medicine, King George's Medical University, UP, Lucknow.

Figure 2: High resolution USG of the bulge showing an oval hypochoic shadow

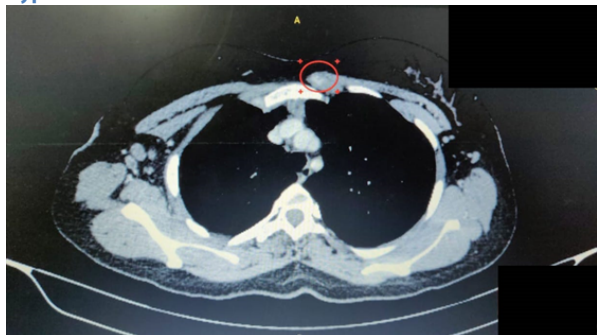


Figure 3: Axial section of CECT thorax demonstrating the hemangioma which takes up the contrast.

Differential diagnosis:

A spontaneous reducible swelling arising from intercostal space could be lung herniation. Lung herniation could be congenital or secondary to trauma or weakening of overlying muscles. The most common site of lung herniation through the thoracic cage is parasternal or thoracic inlet due to weak muscular support in these regions. Our patient had a bulge in left parasternal region thus making spontaneous pulmonary herniation (SPH) a strong differential.

In our case, the bulge appeared only when the patient bent forward and there was no relation with respiration. A SPH would increase on inspiration and decrease on expiration. She was asked to cough and perform valsalva manoeuvre. A herniated lung would increase in size and show cough impulse, however, in our case it did not. On palpation, a SPH could be crepitant and the margins of the overlying muscular defect can often be felt. However, our patient had a firm reducible bulge and the muscular defect could not be appreciated. On CECT thorax, the hemangioma took up the contrast while a SPH would not have.

Treatment:

After explaining the nature of lesion to her, she was referred to the department of surgery for further management and was advised surgical excision and repair of the overlying defect. Other options including conservative management including use of non-steroidal anti-inflammatory drugs, embolization, sclerotherapy or radiotherapy were advised as well.

She decided in favor of conservative management.

Outcome and follow up:

The patient opted for conservative management and is symptomatically stable for last three months.

DISCUSSION

Hemangiomas are benign vascular malformations which are usually congenital or rarely may occur following trauma.⁶ They usually present as mucocutaneous lesions and skeletal muscle hemangiomas are quite infrequent.⁷ While exact incidence and prevalence of intramuscular hemangiomas is not known, they account for about 0.7% of all benign soft tissue tumors.^{8,9} These can arise secondary to trauma but mostly are congenital in origin. Wierzbicki JM et al reviewed the literature on skeletal muscle hemangiomas and concluded that magnetic resonance imaging is the investigation of choice and conservative management is the treatment of choice for this entity. Most of the cases reviewed by them were confined to the lower extremity, most commonly in the quadriceps femoris followed by the calf muscles.¹⁰ Intercostal herniation of skeletal muscle hemangioma has been reported

before by Winchester et al,¹¹ but herniation of a hemangioma only with gravitational effect has not been reported so far.

The insidious onset, history of chronic pain and lack of clinical suspicion makes diagnosis quite difficult. In our case, spontaneous reducibility further confused us. However, imaging modalities can confirm the diagnosis by making its vascularity evident. An initial radiograph followed by ultrasonography with Doppler is useful and can rule out phleboliths. Computed tomography may help to rule out other differentials and MRI remains the best non-invasive investigation modality for soft tissue lesions.¹⁰

As it is a benign pathology, patient may choose conservative management which includes compression garments, non-steroidal anti-inflammatory drugs, physical therapy and limb elevation in case of limb involvement.¹² Other options are embolization/radiotherapy/sclerotherapy or surgical excision of the hemangioma depending upon the symptom status and extent of the tumor.^{13,14} The most common complication following excision is hemorrhage and the risk of recurrence is high varying between 18-61%.¹⁵

Learning points:

- Apart from lung herniation, a palpable, reducible swelling in intercostal region associated with pain could be due to a soft tissue tumor arising from an overlying muscular defect which makes it reducible. In our case it was a hemangioma.
- Skeletal muscle hemangiomas are often misdiagnosed due to their infrequent occurrence and low index of clinical suspicion. In case of a chronic, painful, firm swelling arising from a muscular region, a differential of hemangioma should be kept in mind.
- The vascularity of a skeletal muscle hemangioma helps to differentiate it from other soft tissue masses. It can be made evident on contrast studies.

Author contribution:

Conceptualization: S. K. Verma

Data curation: Richa Tyagi

Supervision: Anand Srivastava, Rajiv Garg

Validation: S. K. Verma

Writing – original draft: Richa Tyagi

Writing – review & editing: S. K. Verma

REFERENCES:

1. Hauser M, Werder W, Largiadèr F, Glazer GM. Lung herniation through a postthoracoscopy chest wall defect - Demonstration with spiral CT. *Chest* 1997;112:558-60.
2. Weissberg D, Refaely Y. Hernia of the lung. *Ann Thoracic Surg* 2002;74:1963-66.
3. Temes RT, Talbot WA, Green DP, Wernly JA. Herniation of the lung after video- assisted thoracic surgery. *Ann Thoracic Surg* 2001;72:606-07.
4. Goverde P, Van Schil P, Van den Brande F, Vanmaele R. Chronic herniation of the lung in a patient with chronic obstructive pulmonary disease. *Thorac Cardiovasc Surg* 1998;46:164-66.
5. Patnaik S, Kumar P, Nayak B, Mohapatra N. Intramuscular Arteriovenous Hemangioma of Thigh: A Case Report and Review of Literature. *J Orthop Case Rep* 2016;6:20-23.
6. Scott JES. Hemangiomas in skeletal muscle. *Br J Surg* 1957;44:496-501.
7. Watson WL, McCarthy WD. Blood and lymph vessel tumors. A report of 1,056 cases. *Surg Gynecol Obstet* 1940;71:569-88.
8. Cohen AJ, Youkey JR, Clagett GP, Huggins M, Nadalo L, d'Avis JC. Intramuscular hemangioma. *JAMA* 1983;249(19):2680-2.
9. Watson WL, McCarthy WD. Blood and lymph vessel tumors. *Surg Gynecol Obstet* 1940;71:569.
10. Wierzbicki JM, Henderson JH, Scarborough MT, Bush CH, Reith JD, Clugston JR. Intramuscular hemangiomas. *Sports Health* 2013;5(5):448-454.

11. David J Winchester, Thomas A Victor, Willard A Fry. Intercostal Hemangioma Presenting as a Chest Wall Tumor. *Ann Thoracic Surg* 1992;54:145-6.
13. Mitty HA, Kleiger B. Partial embolization of large peripheral hemangioma for pain controls. *Radiology* 1978;127:671-72.
14. Wild AT, Raab P, Krauspe R. Hemangioma of skeletal muscle. *Arch Orthop Trauma Surg* 2000;120:139-43.
15. Bella GP, Manivel JC, Thompson RC Jr, Clohisy DR, Cheng EY. Intramuscular hemangioma: recurrence risk related to surgical margins. *Clin Orthop Relat Res* 2007 Jun;459:186-91.